

## PERINEAL RELAPSE OF PROSTATE CARCINOMA

---



**San Bortolo Hospital CyberKnife® Team:**

Radiation Oncologists: Gino Panizzoni, M.D.  
Rosabianca Guglielmi, M.D.

Neurosurgeon/  
Radiation Oncologist: Federico Colombo, M.D.

Medical Physicists: Paolo Francescon, Ph.D.  
Carlo Cavedon, Ph.D.  
Stefania Cora, Ph.D.  
Paolo Scalchi, Ph.D.

Urologist: Andrea Tasca, M.D.

CyberKnife Center: San Bortolo Hospital  
Vincenza, Italy

## PERINEAL RELAPSE OF PROSTATE CARCINOMA

### DEMOGRAPHICS

**Sex:** M  
**Age:** 67  
**Histology:** Adenocarcinoma (Gleason = 9 (5 + 4))

### CLINICAL HISTORY

**Referred by:** Urologist  
**Past Medical History:** Hormonal therapy, radical prostatectomy, conformal radiotherapy

### Case History

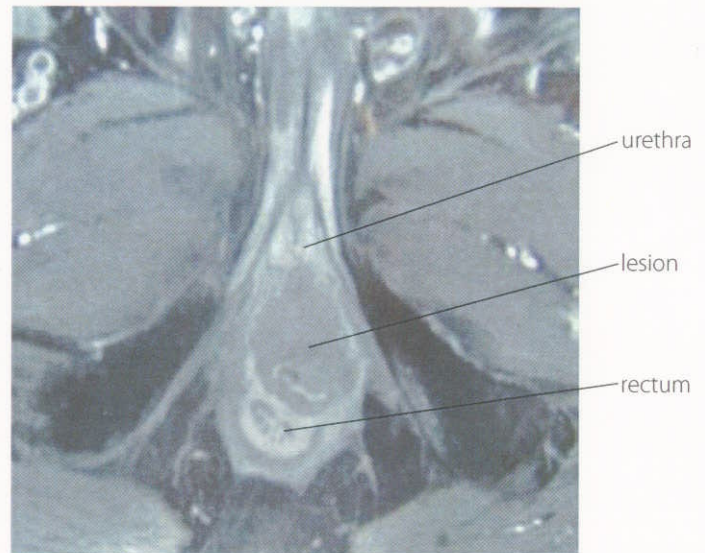
This 67-year-old male was diagnosed with prostate carcinoma, with a PSA of 18 ng/ml. Treatment commenced with neoadjuvant hormonal therapy (bicalutamide 150 mg/day). Three months later a radical prostatectomy was performed. An adenocarcinoma with necrosis, angiolymphatic and perineural infiltrations was found.

Hormonal adjuvant therapy (bicalutamide 50 mg/day) was pursued and conformal adjuvant radiotherapy was performed three months after surgery, reaching a dose of 64 Gy in 32 fractions. Four months later the patient developed a perineal relapse in the apex region, near the posterior urethra, confirmed by histology and apparent on rectal examination as a 4 cm diameter mass. Hormonal therapy was terminated.

The patient began to experience perineal pain, rectal and urinary incontinence, and his PSA increased to 21.4 ng/ml two months after cessation of hormone therapy. The only surgical option was radical pelvicctomy, which was refused by the patient. Further radiotherapy and IMRT were excluded because of the dose already delivered.

### CyberKnife® Treatment Rationale

We hypothesized that stereotactic radiosurgery may provide a similar benefit to surgery with the advantage of sparing the pelvic organs from major toxicity. The CyberKnife System has made extracranial radiosurgery possible by coupling highly conformal radiation delivery with precise targeting based on real-time imaging. We selected this technique for this patient in order to avoid the significant morbidity associated with further surgery.



*Pre-treatment T2-weighted MRI. The lesion is shown after radical prostatectomy, near the urethra, and with infiltration of the anal sphincter. The lesion diameter is 5 cm.*